

Ode to Valveman

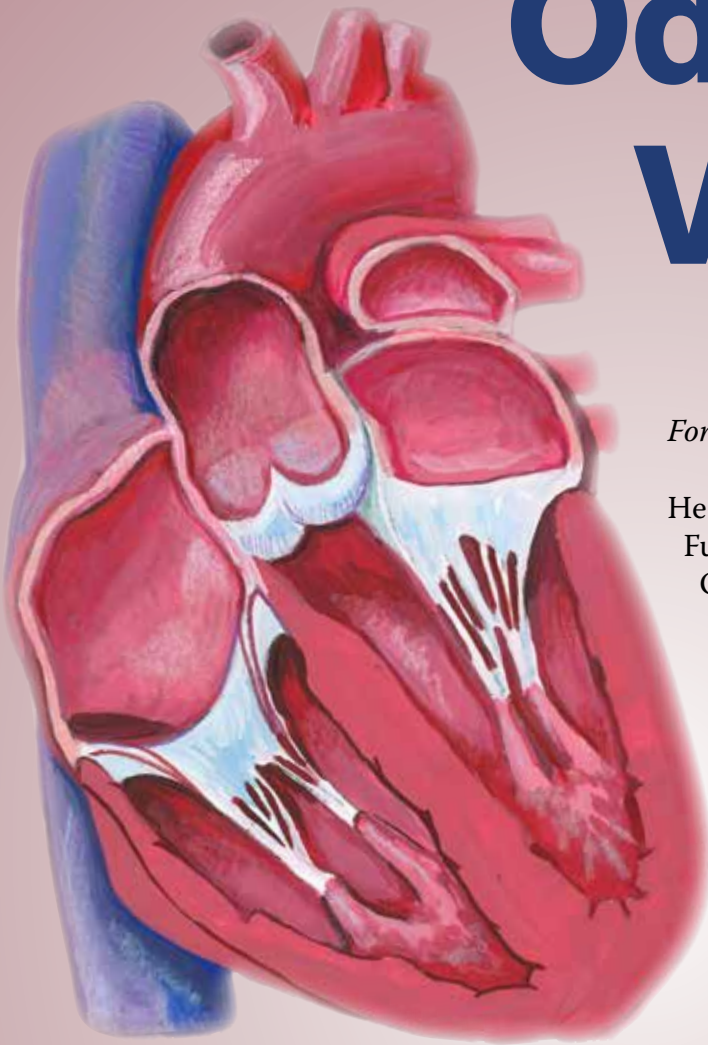


Illustration by Steve Derrick

For Greg P.

He had the normal four from the get-go
Functioning efficiently day and night.
Opening wide for forward flow
Preventing regurge by closing tight.

His mitral went first, insufficient and weak
Blood reversing up into the atrium.
Initial repair with a new technique
Gave promised relief and then some.

Re-do followed using old-school ways
Fixing two, not just the one.
His heart once again seemed healthy and gay
However, Valveman was not yet done.

Three of the four now caused a ripple
Confirmed by tests and scans ultrasonic.
Aortic joined the two making it a triple
Leaving only as native, the pulmonic.

Skillful repair has him back minus murmurs
A heartfelt prognosis as he mends.
Recovery and rehab will make them long-termers
With the love of wife, family, and friends.

—George Ordway, PhD, PA